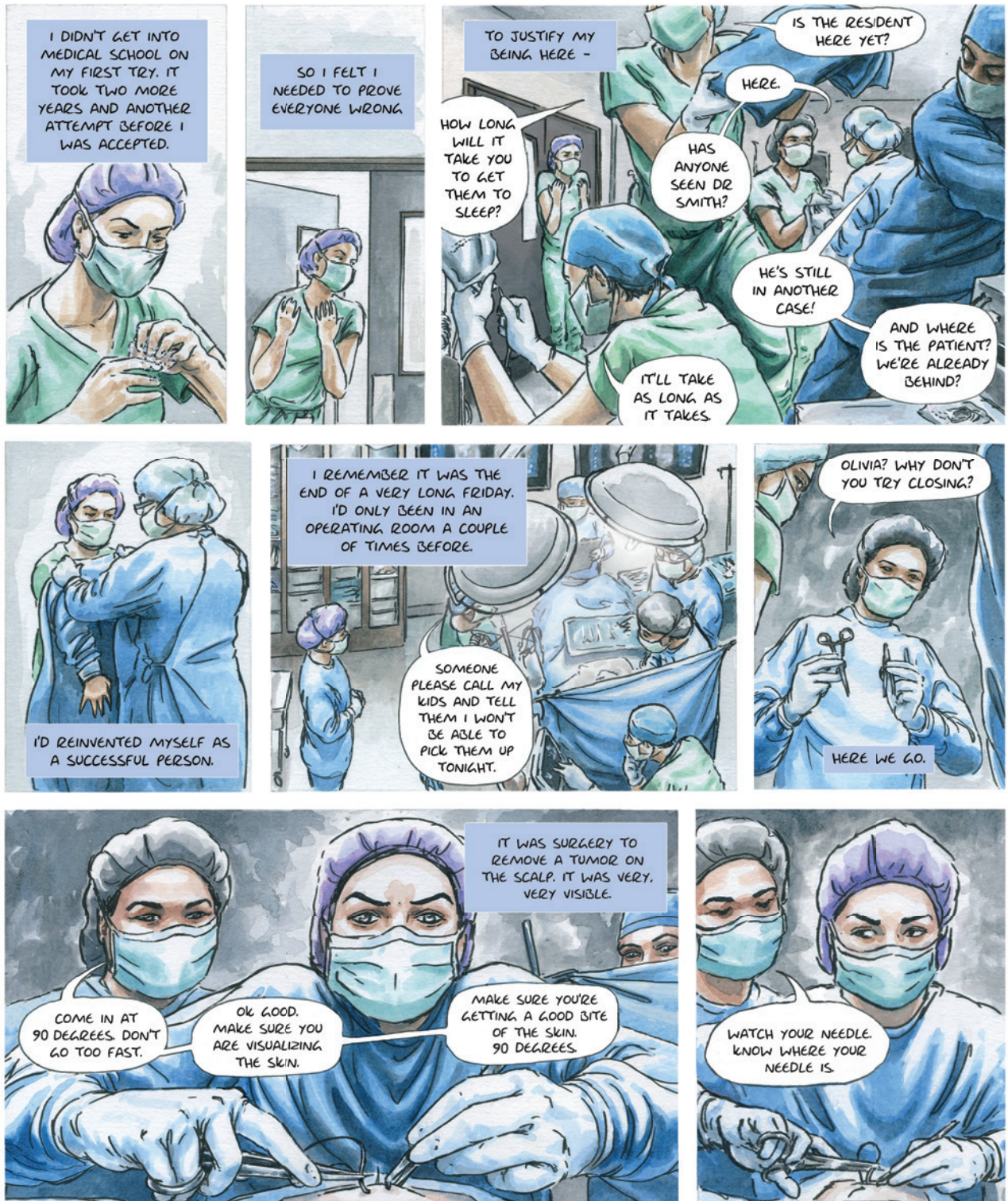
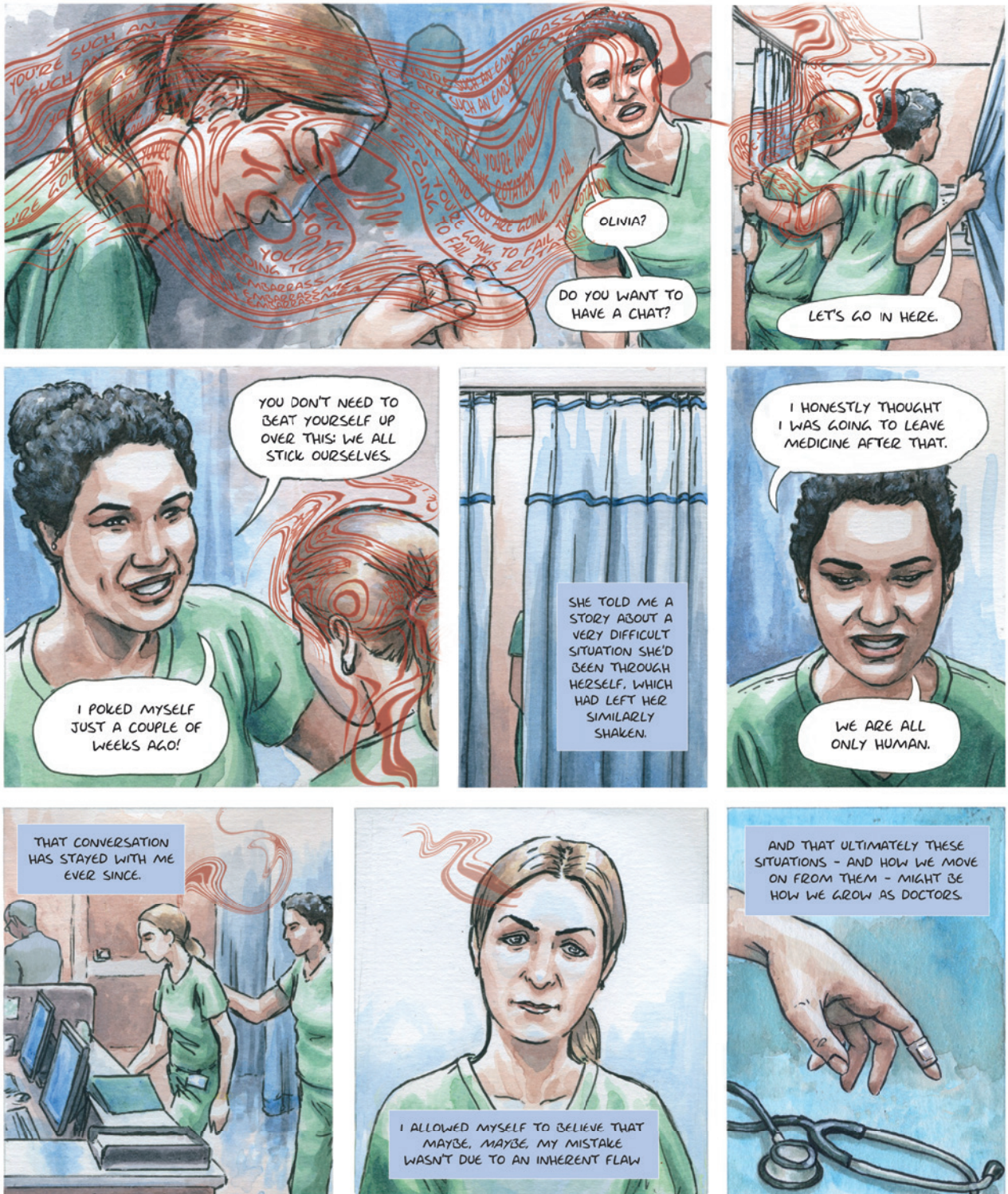


Needlestick

Olivia M.T. Davies, M.D., Luna Dolezal, Ph.D., William E. Bynum IV, M.D., and Charlotte Wu, M.D.; Hannah Berry, *illustrator*







Disclosure forms provided by the authors are available with the full text of this article at NEJM.org.

From Massachusetts General Hospital, Boston (O.M.T.D.); the University of Exeter, Exeter,

United Kingdom (L.D.); Duke University, Durham, NC (W.E.B.); and Harness Health Global, London (C.W.).

The resident depicted in this graphic is Dr. Hillary Newsome.

This article was published on April 23, 2022, and updated on April 29, 2022, at NEJM.org.

DOI: 10.1056/NEJMp2201012

Copyright © 2022 Massachusetts Medical Society.