

RESEARCH ARTICLE

Corneal Confocal Microscopy Detects Neuropathy in Patients with Type 1 Diabetes without Retinopathy or Microalbuminuria

Ioannis N. Petropoulos^{1,2☯‡}, Patrick Green^{1☯‡}, Agnes W. S. Chan³, Uazman Alam¹, Hassan Fadavi¹, Andrew Marshall¹, Omar Asghar¹, Nathan Efron⁴, Mitra Tavakoli¹, Rayaz A. Malik^{1,2*}

1 Centre for Endocrinology and Diabetes, Institute of Human Development, University of Manchester and Central Manchester National Health System Foundation Trust, Manchester Academic Health Science Centre, Manchester, United Kingdom, **2** Weill Cornell Medical College Qatar, Division of Research, Qatar Foundation, Education City, Doha, Qatar, **3** Queen Mary's University, Bart's and London National Health System Trust, London, United Kingdom, **4** Institute of Health and Biomedical Innovation and School of Optometry and Vision Science, Queensland University of Technology, Brisbane, Australia

☯ These authors contributed equally to this work.

‡ These authors are joint first authors on this work.

* ram2045@qatar-med.cornell.edu



OPEN ACCESS

Citation: Petropoulos IN, Green P, Chan AWS, Alam U, Fadavi H, Marshall A, et al. (2015) Corneal Confocal Microscopy Detects Neuropathy in Patients with Type 1 Diabetes without Retinopathy or Microalbuminuria. PLoS ONE 10(4): e0123517. doi:10.1371/journal.pone.0123517

Academic Editor: Soroku Yagihashi, Hirosaki University Graduate School of Medicine, JAPAN

Received: October 30, 2014

Accepted: February 19, 2015

Published: April 8, 2015

Copyright: © 2015 Petropoulos et al. This is an open access article distributed under the terms of the [Creative Commons Attribution License](http://creativecommons.org/licenses/by/4.0/), which permits unrestricted use, distribution, and reproduction in any medium, provided the original author and source are credited.

Data Availability Statement: All data from this study are included in the paper. All study related files are available from Figshare: <http://dx.doi.org/10.6084/m9.figshare.1318406>

Funding: This study was sponsored by awards from the National Institutes of Health, grant number R105991 (<http://www.nih.gov>) and the Juvenile Diabetes Research Foundation International, grant number 27-2008-362 (<http://www.jdrf.org/>). The funders had no role in study design, data collection and analysis, decision to publish, or preparation of the manuscript.

Abstract

Objective

Corneal innervation is increasingly used as a surrogate marker of human diabetic peripheral neuropathy (DPN) however its temporal relationship with the other microvascular complications of diabetes is not fully established. In this cross-sectional, observational study we aimed to assess whether neuropathy occurred in patients with type 1 diabetes, without retinopathy or microalbuminuria.

Materials and Methods

All participants underwent detailed assessment of peripheral neuropathy [neuropathy disability score (NDS), vibration perception threshold (VPT), peroneal motor nerve conduction velocity (PMNCV), sural sensory nerve conduction velocity (SSNCV) and in vivo corneal confocal microscopy (IVCCM)], retinopathy (digital fundus photography) and albuminuria status [albumin: creatinine ratio (ACR)].

Results

53 patients with Type 1 diabetes with (n=37) and without retinopathy (n=16) were compared to control subjects (n=27). SSNCV, corneal nerve fibre (CNFD) and branch (CNBD) density and length (CNFL) were reduced significantly (p<0.001) in diabetic patients without retinopathy compared to control subjects. Furthermore, CNFD, CNBD and CNFL were also significantly (p<0.001) reduced in diabetic patients without microalbuminuria (n=39), compared to control subjects. Greater neuropathic severity was associated with established retinopathy and microalbuminuria.

Competing Interests: The authors have declared that no competing interests exist.

Conclusions

IVCCM detects early small fibre damage in the absence of retinopathy or microalbuminuria in patients with Type 1 diabetes.

Introduction

Diabetes and its complications represent a growing global health burden, affecting over an estimated 366 million people worldwide [1]. The triad of retinopathy, nephropathy and neuropathy are well recognised microvascular complications, and are the leading causes of premature blindness, end-stage renal failure, foot ulceration and amputation, respectively [2]. Once established, they have a major impact on the quality of life of patients with diabetes and are associated with adverse healthcare outcomes [3].

Diabetic retinopathy (DR) is strongly associated with nephropathy [4], and is one of the earliest microvascular complications [5]. However, recent studies have shown that early neuronal abnormalities, such as altered multi-focal electroretinogram (mfERG) responses [6], retinal nerve fibre layer thinning [7] and loss of central visual field sensitivity [8] occur before the onset of overt vascular lesions in the retina, and may be of prognostic value. Krolewski et al. have previously found a strong association between cardiac autonomic neuropathy (CAN) and proliferative DR (PDR) in patients with type 1 diabetes suggesting an underlying etiologic link [9]. Indeed, the Rochester Diabetic Neuropathy Study has shown that markers of microvessel damage such as DR and proteinuria or microalbuminuria (MA) are the strongest predictors for the severity of DPN [10].

Recently, corneal nerve morphology assessed by IVCCM has been proposed as an early surrogate marker for small nerve fibre damage in DPN [11, 12]. Furthermore, corneal nerve fibre length correlates with clinical and electrophysiological measures of diabetic peripheral neuropathy [13, 14] and long term glycaemic control [15, 16]. Recent studies have shown a stepwise deterioration in corneal nerve morphology in healthy subjects and patients with pre-proliferative and PDR [17, 18]. The exact temporal relationship between neuropathy and retinopathy or nephropathy however remains unclear. The purpose of this cross-sectional, observational study was to establish whether neuropathy determined using the highly sensitive techniques of IVCCM and neurophysiology was present in patients with Type 1 diabetes without retinopathy or microalbuminuria.

Materials and Methods

Study subjects

80 subjects in total (53 with type 1 diabetes and 27 controls) were assessed in this study. Participants were excluded if they had a positive history of malignant, connective tissue or infectious disease, deficiency of vitamin B₁₂ or folate, chronic renal failure, liver failure, active diabetic foot ulcers, family history of peripheral neuropathy. Participants were also excluded if they had active ocular disease (except for DR), systemic disease known to affect the cornea other than diabetes or chronic corneal pathologies. Inclusion criteria for patients with diabetes mellitus were a previous clinical diagnosis of type 1 diabetes, confirmed by laboratory biochemistry, and age between 18–85 years old. Controls were confirmed not to have diabetes also by laboratory testing and were of the same age range.

Ethics Statement and data availability

This study adhered to the tenets of the Declaration of Helsinki and was approved by the North Manchester Research Ethics Committee. Study subjects with diabetes were recruited from the Manchester Diabetes Centre and control subjects were recruited from the community or were relatives of the subjects with diabetes. Informed written consent was obtained from all subjects prior to participation after explanation of the nature and possible consequences of the study. The full, anonymised dataset can be found at <https://researchdata.ands.orf.au/longitudinal-assessment-neuropathy-markers-landmark/461294>.

Clinical assessment

All study participants underwent assessment of HbA_{1c} (%), lipid fractions [total cholesterol (TC) (mmol/l), high (HDL) and low density lipoprotein cholesterol (LDL) (mmol/l), triglycerides (mmol/l)] and albumin to creatinine ratio (ACR) (mmol/l).

Peripheral Neuropathy assessment

The modified neuropathy disability score (NDS) was assessed [19]. VPT was tested on the hallux using a Neuroesthesiometer (Horwell, Scientific Laboratory Supplies, Wilford, Nottingham, UK). Electro-diagnostic studies were undertaken using a Dantec “Keypoint” system (Dantec Dynamics Ltd, Bristol, UK) and peroneal motor and sural sensory nerves [peroneal motor nerve amplitude (PMNCV), sural sensory nerve amplitude (mV) and peroneal motor nerve conduction velocity (PMNCV), sural sensory nerve conduction velocity (SSNCV) (m/s)] were assessed in the left lower limb (calf-to-ankle) by a consultant neurophysiologist.

In-Vivo Corneal Confocal Microscopy

All study subjects were scanned with a laser IVCCM [Heidelberg Retinal Tomograph III Rostock Cornea Module (Heidelberg Engineering GmbH, Heidelberg, Germany)]. This IVCCM uses a 670 nm wavelength helium neon diode laser, which is a class I laser and therefore does not pose any ocular safety hazard. A 63x objective lens with a numerical aperture of 0.9 and a working distance, relative to the applanating cap (TomoCap[®], Heidelberg Engineering GmbH, Heidelberg, Germany) of 0.0 to 3.0 mm was used. The size of each two-dimensional image produced was 384 μ m x 384 μ m which has a 15° x 15° field of view and 10 μ m/pixel transverse optical resolution. This type of IVCCM uses an entirely digital image capture system and all images are stored in an external hard drive.

A drop of 0.4% benoxinate hydrochloride (Chauvin Pharmaceuticals, Chelmsford, UK) was used to anaesthetise each eye and Viscotears (Carbomer 980, 0.2%, Novartis, UK) were used as the coupling agent between the cornea and the applanating cap. All subjects were asked to fixate on an outer fixation light throughout the IVCCM scan and a CCD camera was used to image the cornea and correctly position the applanating cap onto the corneal apex. The overall examination took approximately 5 minutes for both eyes of each subject and in this study two experienced optometrists performed all IVCCM scans. All images were captured using the “section” mode in the Heidelberg Explorer of the HRT III RCM. 5 to 8 images provide an acceptable level of accuracy to quantify the corneal subbasal nerve morphology [20]. We selected and analysed 6 high clarity images/subject from the central subbasal nerve plexus. Criteria for image selection were depth, focus position and contrast.

Image Analysis

One examiner masked from cardiometabolic, peripheral neuropathy and retinopathy status quantified subbasal nerve morphology in 480 images of all study participants, using semi-automated, purpose-written, proprietary software (CCMetrics, M. A. Dabbah, Imaging Science Biomedical Engineering, University of Manchester, Manchester, UK). The specific parameters measured per frame were those we have previously established [12]: CNFD (no./mm²), CNBD (no./mm²) and CNFL (mm/mm²). Specific details on the definition and measurement of each parameter can be found elsewhere [21].

Study definition for retinopathy and nephropathy

The grade of retinopathy for patients with diabetes was defined as the most recent result (1 or more examinations per annum) obtained from the UK NHS Diabetic Eye Screening Programme (the full scope of the programme can be accessed here: <http://diabeticeye.screening.nhs.uk/service-specification>), which is responsible for providing nationwide retinal screening for patients with diabetes mellitus (the latest DR grading criteria as set by the Royal College of Ophthalmologists can be found at: <http://www.rcophth.ac.uk/news.asp?itemid=1016&itemTitle=DIABETIC+RETINOPATHY+GUIDELINES+ADDED§ion=24§ionTitle=News>). Patients with “background retinopathy” or greater were classified as “with retinopathy”. To rule out retinopathy in control subjects, a standard field fundus photograph was captured using a Canon CR-2 Plus digital, non-mydratic retinal camera (Canon Healthcare Technologies, Melville, New York, USA) and the image was graded by a study certified optometrist using the criteria proposed by the Early Treatment of Diabetic Retinopathy Study [22]. To be eligible for the study, control subjects (determined by assessment of their cardio-metabolic status and medical history) had to have a gradable ocular fundus image in at least one eye. If signs of retinopathy were found the participant was informed and excluded from the study. Albuminuria was determined using the albumin-to-creatinine ratio (ACR) and microalbuminuria (MA) in this study was defined as an ACR >2.5 mg / mmol in males and >3.5 mg / mmol in females. Similarly, control subjects with an abnormal ACR were informed and excluded from the study.

Statistical analysis

Statistical analysis was performed using SPSS for Windows XP (Version 16.05.0, IBM, NY, USA) and graphs were generated with OriginPro for Windows XP (Version 8.5.0 SR1, OriginLab Corporation, Northampton, MA, USA). All data are expressed as mean ± SEM. Variables were tested for normality by means of univariate analysis, histograms and the Shapiro-Wilk test. One-way analysis of variance or non-parametric Kruskal Wallis was used to the test for differences between the means. Post-hoc analysis (Tukey) was performed and after correction for multiple testing (Bonferroni) a $P < 0.05$ was considered significant.

Results

Clinical assessment

Detailed clinical and demographic results are presented in [Table 1](#). Briefly, diabetic patients (duration 28.6 ± 2.2 years) compared to control subjects had similar age (49.7 ± 2.1 v 49.7 ± 2.3 , $P > 0.05$) and BMI (27.0 ± 0.6 v 27.9 ± 0.9), higher HbA1c (%) (8.3 ± 0.3 v 5.6 ± 0.1 , $P < 0.001$), a significantly lower TC (4.2 ± 0.2 v 5.2 ± 0.2 , $P < 0.001$), LDLC (2.1 ± 0.1 v 3.0 ± 0.1 , $p < 0.001$), serum triglycerides (1.2 ± 0.1 v 1.7 ± 0.2 , $P < 0.005$) and comparable HDLC (1.6 ± 0.2 v 1.5 ± 0.1 , $P > 0.05$).

Table 1. Demographic results for study participants stratified according to retinopathy and nephropathy status.

Group	Age	T1D Duration (Years)	HbA1c (%)	BMI (kg/m ²)	ACR (mg/mmol)	TC (mmol/mol)	HDLC (mmol/mol)	LDLC (mmol/mol)	Trigs (mmol/mol)
Controls (n = 23)	49.7 ± 2.1	N/A	5.6 ± 0.1	27.9 ± 0.9	0.8 ± 0.1	5.2 ± 0.2	1.5 ± 0.1	3.0 ± 0.1	1.7 ± 0.2
Diabetes No DR (n = 17)	43.5 ± 13.6	19.2 ± 4.0	8.0 ± 0.3†	26.5 ± 1.3	0.9 ± 0.2	4.3 ± 0.3†	1.5 ± 0.1	2.2 ± 0.3†	1.1 ± 0.2†
Diabetes DR (n = 36)	52.3 ± 15.8‡	32.7 ± 2.4‡	8.4 ± 0.3†	27.1 ± 0.7	4.0 ± 1.4‡ †	4.1 ± 0.1†	1.6 ± 0.1	2.0 ± 0.2†	1.3 ± 0.1†
Diabetes No MA (n = 39)	46.9 ± 2.9	25.7 ± 2.9	8.1 ± 0.2*	27.5 ± 1.8	0.9 ± 0.1	4.1 ± 0.2*	1.6 ± 0.1	2.0 ± 0.8*	1.1 ± 0.2*
DiabetesMA (n = 14)	55.9 ± 4.8**	35.1 ± 4.2**	8.8 ± 0.8* **	25.3 ± 1.4	6.1 ± 2.0* **	4.3 ± 0.3*	1.6 ± 0.1	2.2 ± 0.8	1.3 ± 0.1*

Results are expressed as mean ± SEM. For patients with diabetes stratified according to retinopathy status:

† significantly different from controls,

‡ significantly different from “diabetes without DR”.

For patients with diabetes stratified according to albuminuria status:

* significantly different from controls,

** significantly different from “diabetes without MA”.

A P <0.05 was considered significant.

doi:10.1371/journal.pone.0123517.t001

Neuropathy assessment

Detailed neuropathy results for patients stratified according to their retinopathy or microalbuminuria status are presented in [Table 2](#).

Neuropathy vs. retinopathy

Patients without DR compared to control subjects showed a significantly lower CNFD (P = 0.0001), CNBD (P<0.0001), CNFL (P<0.0001) and SNCV (P<0.05). There was a further

Table 2. Neuropathy measurements in controls and patients with Type 1 diabetes stratified according to retinopathy or microalbuminuria status.

Group	NDS	VPT (V)	SSNA (µV)	SSNCV (m/s)	PMNA (µV)	PMNCV (m/s)	CNFD (no./mm ²)	CNBD (no./mm ²)	CNFL (mm/mm ²)
Controls (n = 23)	0.4 ± 0.2	6.8 ± 1.1	16.4 ± 1.7	50.2 ± 0.8	5.4 ± 0.4	48.1 ± 0.6	37.1 ± 1.3	101.7 ± 7.4	27.7 ± 1.1
<i>Neuropathy in patients with and without diabetic retinopathy</i>									
Diabetes No DR (n = 17)	1.8 ± 0.7	8.7 ± 2.1	11.8 ± 1.5	45.9 ± 1.6 †	7.8 ± 3.1	44.8 ± 0.8	28.1 ± 2.3 †	56.1 ± 6.9 †	20.6 ± 1.5 †
Diabetes DR (n = 36)	3.5 ± 0.5 †	17.7 ± 2.2 †	7.3 ± 1.0 †	42.3 ± 0.9 ‡	3.3 ± 0.7 †	39.0 ± 1.2 †	22.1 ± 1.2 ‡	49.9 ± 4.8	17.4 ± 0.9
<i>Neuropathy in patients with and without microalbuminuria</i>									
Diabetes No MA (n = 39)	2.1 ± 0.5 *	10.9 ± 1.6	9.9 ± 1.2	44.5 ± 1.0	5.7 ± 1.7	42.7 ± 1.0	26.3 ± 1.5 *	56.7 ± 5.5 *	19.9 ± 1.7 *
Diabetes MA (n = 14)	5.2 ± 1.0 **	25.0 ± 4.7 **	5.5 ± 1.6 *	40.5 ± 1.7 *	1.8 ± 0.5	35.5 ± 2.4 *	17.3 ± 2.0 **	37.9 ± 7.0 **	14.3 ± 1.7 **

Results are expressed as mean ± SEM. For patients with diabetes stratified according to retinopathy status:

† significantly different from controls,

‡ significantly different from “diabetes no DR”.

For patients with diabetes stratified according to albuminuria status:

* significantly different from controls,

** significantly different from “diabetes no MA”.

A P <0.05 was considered significant.

doi:10.1371/journal.pone.0123517.t002

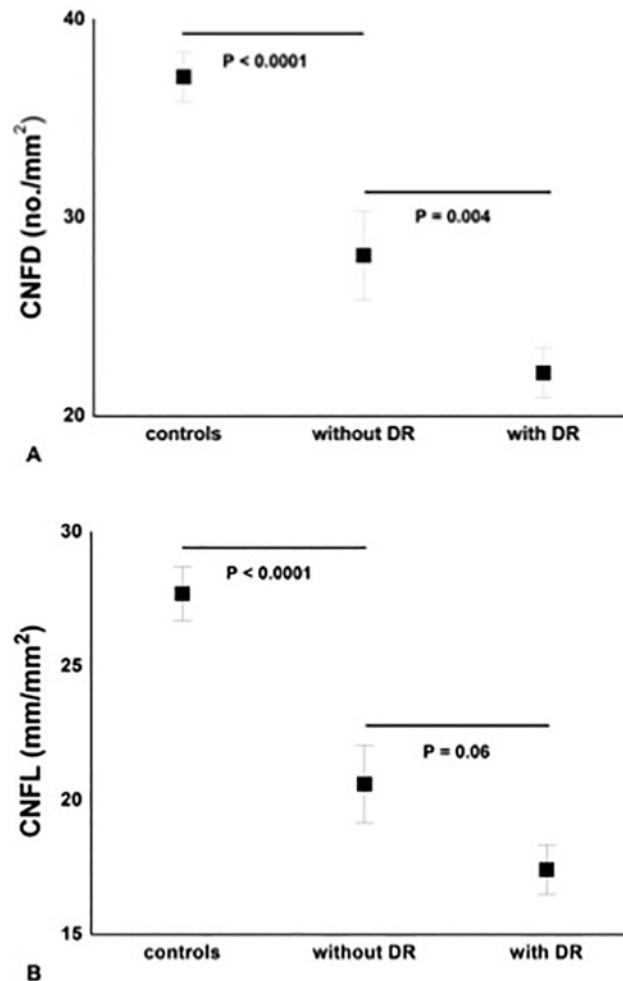


Fig 1. Significant and progressive loss of CNFD (A) and CNFL (B) between controls, diabetic patients ‘without DR’ (n = 17) and ‘with DR’ (n = 36). Results are expressed as mean ± SEM.

doi:10.1371/journal.pone.0123517.g001

significant reduction in CNFD between patients with and without DR ($P = 0.004$) (Figs 1 and 2 and Table 2). There was an inverse correlation between the retinopathy grade and CNFD ($r = -0.67, P < 0.001$), CNBD ($r = -0.58, P < 0.001$) and CNFL ($r = -0.66, P < 0.001$).

Neuropathy vs. microalbuminuria

Diabetic patients without MA compared to control subjects had a significant reduction in CNFD ($P < 0.0001$), CNBD ($P = 0.001$) and CNFL ($P < 0.0001$). There was a further significant reduction for CNFD ($P = 0.002$), CNBD ($P = 0.02$), CNFL ($P = 0.006$) and PMNA ($P < 0.001$) in patients with MA (Fig 3 and Table 2).

Discussion

Diabetic microvascular complications result in considerable morbidity and both microalbuminuria and the severity of DR relate to the severity of DPN [10]. However, the temporal

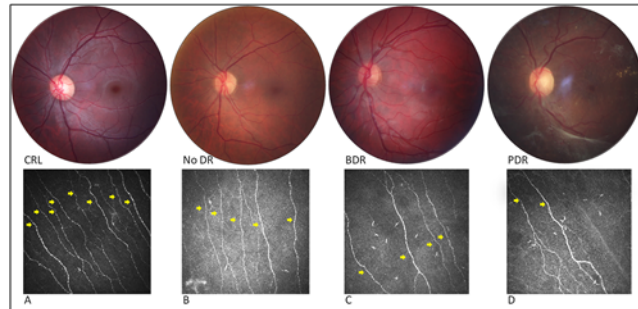


Fig 2. Fundus photograph of the central 30° with corresponding IVCCM image of the central subbasal nerves (yellow arrows) for control (non-mydratic) (CTR) (A) and patients with diabetes and varying stages of DR (B, C and D). From left to right: (A) IVCCM image shows abundant corneal nerve axons for a control without retinopathy, (B) significant decrease of subbasal nerves in a patient with diabetes ‘without DR’ (No DR), (C) slight progressive loss of subbasal nerves in a patient with diabetes and background DR (BDR) and (D) severe axonal loss on IVCCM in a patient with diabetes and pre-proliferative DR (PDR).

doi:10.1371/journal.pone.0123517.g002

relationship for the development of the microvascular complications has been systematically assessed in very few studies. The United Kingdom Prospective Diabetes Study estimated the prevalence of DPN, defined as loss of vibration perception, at ~7% [23], DR at 35–39% [24] and MA at 7% at diagnosis of Type 2 diabetes [25]. In another population based study of

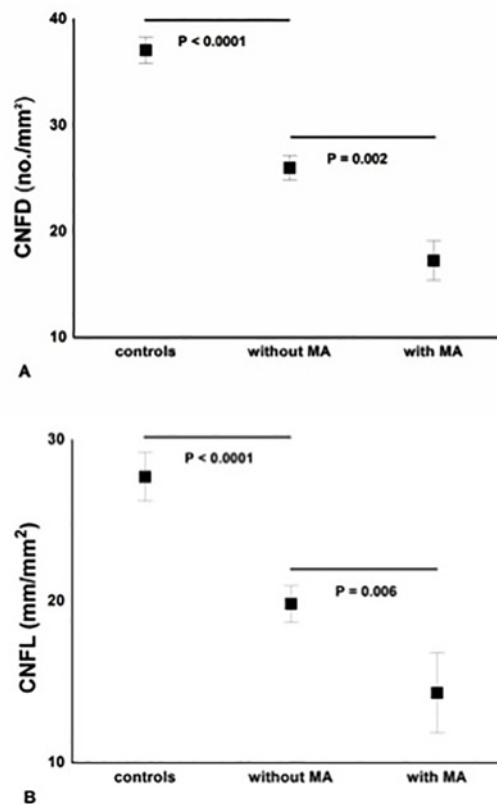


Fig 3. Significant and progressive loss of CNFD (A) and CNFL (B) between controls, diabetic patients ‘without MA’ (n = 39) and ‘with MA’ (n = 14). Results are expressed as mean ± SEM.

doi:10.1371/journal.pone.0123517.g003

newly diagnosed patients with Type 2 diabetes, DPN was present in 19%, retinopathy in 5% and nephropathy in 37%-48% [26]. A major limitation of these studies is the use of variable definitions for neuropathy, which are subjective and lack sensitivity, and the use of measures which detect neuropathy at an advanced stage compared to more standardized measures of retinal and renal disease, which detect these complications at an earlier stage of disease.

Over the past decade IVCCM has emerged as a novel non-invasive technique to identify early neuropathy [11–14, 27]. The loss of corneal sub-basal innervation detected using IVCCM correlates with peripheral nerve dysfunction, intra-epidermal nerve fiber [13] and retinal nerve fiber layer [7] loss. Furthermore, neuroretinal abnormalities, such as altered mfERG response waveforms, occur in the absence of retinopathy [6] and recently loss of central visual field sensitivity has been related to the severity of DPN [8]. Importantly, prospective evaluation of mfERG responses has shown that signal alterations can predict by precise location impending retinal vasculopathy and/or edema. Previously, the Retinopathy in the Chronic Renal Insufficiency Cohort Study found a strong relationship between DR and urine protein concentration but did not assess the relationship with DPN [4].

The present study shows that IVCCM detects a significant reduction in CNFD, CNBD and CNFL in diabetic patients without DR. This is an important observation as it suggests that neuropathy may precede detectable retinopathy, consistent with recent findings from other centres [17, 18], but also that worsening of retinopathy from no DR to PDR is paralleled by further corneal nerve loss and significant peripheral nerve dysfunction. Previously, a strong link has been found between CAN and PDR [9]. Of pathophysiological relevance, retinal vessels are devoid of sympathetic innervation and depend entirely on blood flow autoregulation, which has been found defective even in diabetic subjects without retinopathy [28] and is further impaired with increasing blood flow [29].

The present study also demonstrates a significant reduction in CNFD, CNFL and CNBD and significant electrophysiological evidence of neuropathy in Type 1 diabetic patients 'without MA', but the observed associations were less strong than with retinopathy, especially in subjects 'with MA'. Only 14 subjects were classified as having 'MA' compared to 36 'with DR'. Moreover, these subjects with MA showed more marked alterations in electrophysiology, clinical testing and IVCCM than those with DR. This suggests that incipient nephropathy may represent a relatively late microvascular complication, which occurs after significant neuropathy and retinopathy have developed [30]. Furthermore, differences may be attributed to the use of urine protein concentration, a measure of glomerular function as opposed to fundus photography and IVCCM both measures of structural damage.

At present retinal photography and microalbuminuria are the endpoints of choice for screening for retinopathy and nephropathy, respectively, and yet the monofilament test, a quick bedside exam, is used for neuropathy screening. This study shows that significant small nerve damage detected using IVCCM is detected in the absence of retinopathy and microalbuminuria. Therefore this challenges the current paradigm for screening strategies deployed to detect the microvascular complications of diabetes. The identification of neuropathy using IVCCM may represent the earliest window of opportunity to intervene and prevent the progression of the triad of microvascular complications. A limitation of this study is the cross-sectional design and the relatively small number of subjects studied. Another limitation is that this study assessed only patients with type 1 diabetes and therefore results may not be directly applicable to all patients with diabetes. However, two recent studies [17, 31] have demonstrated similar findings in patients with type 2 diabetes. Future, prospective studies are needed to establish the exact temporal relationship between the development of neuropathy, retinopathy and nephropathy, and to define the predictive value of IVCCM.

Acknowledgments

This work was presented as an abstract at the 22nd meeting of Neuropathy in Diabetes (NEURODIAB) Study Group of the European Association for the Study of Diabetes. This research was facilitated by the Manchester Biomedical Research Centre and the Greater Manchester Comprehensive Local Research Network.

Author Contributions

Conceived and designed the experiments: RAM. Performed the experiments: PG INP AWSC UA HF AM OA MT. Analyzed the data: PG INP. Contributed reagents/materials/analysis tools: AWSC UA HF OA. Wrote the paper: PG INP NE MT RAM.

References

1. Whiting DR, Guariguata L, Weil C, Shaw J. IDF diabetes atlas: global estimates of the prevalence of diabetes for 2011 and 2030. *Diabetes Research and Clinical Practice*. 2011; 94(3):311–21. doi: [10.1016/j.diabres.2011.10.029](https://doi.org/10.1016/j.diabres.2011.10.029) PMID: [22079683](https://pubmed.ncbi.nlm.nih.gov/22079683/)
2. Fowler MJ. Microvascular and Macrovascular Complications of Diabetes. *Clinical Diabetes*. 2008; 26(2):77–82. doi: [10.2337/diaclin.26.2.77](https://doi.org/10.2337/diaclin.26.2.77)
3. Candrilli SD, Davis KL, Kan HJ, Lucero MA, Rousculp MD. Prevalence and the associated burden of illness of symptoms of diabetic peripheral neuropathy and diabetic retinopathy. *Journal of Diabetes and its Complications*. 2007; 21(5):306–14. PMID: [17825755](https://pubmed.ncbi.nlm.nih.gov/17825755/)
4. Grunwald J, Alexander J, Ying G, Maguire M, Daniel E, Whittock-Martin R, et al. Retinopathy and Chronic Kidney Disease in the Chronic Renal Insufficiency Cohort (CRIC) Study. *Arch Ophthalmol*. 2012; 130(9):1136–44. PMID: [22965589](https://pubmed.ncbi.nlm.nih.gov/22965589/)
5. Lövestam-Adrian M, Agardh E, Agardh C. The temporal development of retinopathy and nephropathy in type 1 diabetes mellitus during 15 years diabetes duration. *Diabetes Research and Clinical Practice*. 1999; 45(1):15–23. PMID: [10499881](https://pubmed.ncbi.nlm.nih.gov/10499881/)
6. Adams AJ, Bearse MA Jr. Retinal neuropathy precedes vasculopathy in diabetes: a function-based opportunity for early treatment intervention? *Clinical and Experimental Optometry*. 2012; 95(3):256–65. doi: [10.1111/j.1444-0938.2012.00733.x](https://doi.org/10.1111/j.1444-0938.2012.00733.x) PMID: [22497728](https://pubmed.ncbi.nlm.nih.gov/22497728/)
7. Shahidi AM, Sampson GP, Pritchard N, Edwards K, Vagenas D, Russell AW, et al. Retinal nerve fibre layer thinning associated with diabetic peripheral neuropathy. *Diabetic Medicine*. 2012; 29(7):e106–e11. doi: [10.1111/j.1464-5491.2012.03588.x](https://doi.org/10.1111/j.1464-5491.2012.03588.x) PMID: [22269030](https://pubmed.ncbi.nlm.nih.gov/22269030/)
8. Sampson G, Shahidi A, Vagenas D, Pritchard N, Edwards K, Russell A, et al. Visual sensitivity loss in the central 30° of visual field is associated with diabetic peripheral neuropathy. *Diabetologia*. 2012:1–7. doi: [10.1007/s00125-012-2694-y](https://doi.org/10.1007/s00125-012-2694-y) PMID: [22945305](https://pubmed.ncbi.nlm.nih.gov/22945305/)
9. Krolewski AS, Barzilay J, Warram JH, Martin BC, Pfeifer M, Rand LI. Risk of early-onset proliferative retinopathy in IDDM is closely related to cardiovascular autonomic neuropathy. *Diabetes*. 1992; 41(4):430–7. PMID: [1607070](https://pubmed.ncbi.nlm.nih.gov/1607070/)
10. Dyck PJ, Davies J, Wilson D, Melton L, O'Brien P. Risk factors for severity of diabetic polyneuropathy: intensive longitudinal assessment of the Rochester Diabetic Neuropathy Study cohort. *Diabetes Care*. 1999; 22(9):1479–86. PMID: [10480512](https://pubmed.ncbi.nlm.nih.gov/10480512/)
11. Tavakoli M, Quattrini C, Abbott C, Kallinikos P, Marshall A, Finnigan J, et al. Corneal Confocal Microscopy A novel noninvasive test to diagnose and stratify the severity of human diabetic neuropathy. *Diabetes Care*. 2010; 33(8):1792–7. doi: [10.2337/dc10-0253](https://doi.org/10.2337/dc10-0253) PMID: [20435796](https://pubmed.ncbi.nlm.nih.gov/20435796/)
12. Malik RA, Kallinikos P, Abbott C, van Schie CHM, Morgan P, Efron N, et al. Corneal confocal microscopy: a non-invasive surrogate of nerve fibre damage and repair in diabetic patients. *Diabetologia*. 2003; 46(5):683–8. PMID: [12739016](https://pubmed.ncbi.nlm.nih.gov/12739016/)
13. Quattrini C, Tavakoli M, Jeziorska M, Kallinikos P, Tesfaye S, Finnigan J, et al. Surrogate markers of small fiber damage in human diabetic neuropathy. *Diabetes*. 2007; 56(8):2148–54. PMID: [17513704](https://pubmed.ncbi.nlm.nih.gov/17513704/)
14. Ahmed A, Bril V, Orszag A, Paulson J, Yeung E, Ngo M, et al. Detection of Diabetic Sensorimotor Polyneuropathy by Corneal Confocal Microscopy in Type 1 Diabetes A concurrent validity study. *Diabetes Care*. 2012; 35(4):821–8. doi: [10.2337/dc11-1396](https://doi.org/10.2337/dc11-1396) PMID: [22323412](https://pubmed.ncbi.nlm.nih.gov/22323412/)
15. Ishibashi F, Okino M, Ishibashi M, Kawasaki A, Endo N, Kosaka A, et al. Corneal nerve fiber pathology in Japanese type 1 diabetic patients and its correlation with antecedent glycemic control and blood pressure. *Journal of Diabetes Investigation*. 2011; 3(2):191–8.

16. Wu T, Ahmed A, Bril V, Orszag A, Ng E, Nwe P, et al. Variables associated with corneal confocal microscopy parameters in healthy volunteers: implications for diabetic neuropathy screening. *Diabetic Medicine*. 2012; 29(9):e297–e303. doi: [10.1111/j.1464-5491.2012.03678.x](https://doi.org/10.1111/j.1464-5491.2012.03678.x) PMID: [22519850](https://pubmed.ncbi.nlm.nih.gov/22519850/)
17. Nitoda E, Kallinikos P, Pallikaris A, Moschandrea J, Amoiridis G, Ganotakis E, et al. Correlation of Diabetic Retinopathy and Corneal Neuropathy Using Confocal Microscopy. *Current Eye Research*. 2012; 37(10):898–906. doi: [10.3109/02713683.2012.683507](https://doi.org/10.3109/02713683.2012.683507) PMID: [22632054](https://pubmed.ncbi.nlm.nih.gov/22632054/)
18. Zhivov A, Winter K, Hovakimyan M, Peschel S, Harder V, Schober HC, et al. Imaging and Quantification of Subbasal Nerve Plexus in Healthy Volunteers and Diabetic Patients with or without Retinopathy. *PLoS one*. 2013; 8(1):e52157. doi: [10.1371/journal.pone.0052157](https://doi.org/10.1371/journal.pone.0052157) PMID: [23341892](https://pubmed.ncbi.nlm.nih.gov/23341892/)
19. Young M, Boulton AJM, MacLeod A, Williams DRR, Sonksen P. A multicentre study of the prevalence of diabetic peripheral neuropathy in the United Kingdom hospital clinic population. *Diabetologia*. 1993; 36(2):150–4. PMID: [8458529](https://pubmed.ncbi.nlm.nih.gov/8458529/)
20. Vagenas D, Pritchard N, Edwards K, Shahidi AM, Sampson GP, Russell AW, et al. Optimal image sample size for corneal nerve morphometry. *Optometry & Vision Science*. 2012; 89(5):812.
21. Petropoulos IN, Manzoor T, Morgan P, Fadavi H, Asghar O, Alam U, et al. Repeatability of In Vivo Corneal Confocal Microscopy to Quantify Corneal Nerve Morphology. *Cornea*. 2013; 32(5):e83–e9. doi: [10.1097/ICO.0b013e3182749419](https://doi.org/10.1097/ICO.0b013e3182749419) PMID: [23172119](https://pubmed.ncbi.nlm.nih.gov/23172119/)
22. Group DRSR. A modification of the Airlie House classification of diabetic retinopathy. Report 7. *Investigative Ophthalmology & Visual Science*. 1981; 21:210–26.
23. Stratton IM, Adler AI, Neil HAW, Matthews DR, Manley SE, Cull CA, et al. Association of glycaemia with macrovascular and microvascular complications of type 2 diabetes (UKPDS 35): prospective observational study. *Bmj*. 2000; 321(7258):405–12. PMID: [10938048](https://pubmed.ncbi.nlm.nih.gov/10938048/)
24. Kohner EM, Aldington SJ, Stratton IM, Manley SE, Holman RR, Matthews DR, et al. United Kingdom Prospective Diabetes Study, 30: diabetic retinopathy at diagnosis of non-insulin-dependent diabetes mellitus and associated risk factors. *Archives of Ophthalmology*. 1998; 116(3):297. PMID: [9514482](https://pubmed.ncbi.nlm.nih.gov/9514482/)
25. Adler AI, Stevens RJ, Manley SE, Bilous RW, Cull CA, Holman RR. Development and progression of nephropathy in type 2 diabetes: the United Kingdom Prospective Diabetes Study (UKPDS 64). *Kidney international*. 2003; 63(1):225–32. PMID: [12472787](https://pubmed.ncbi.nlm.nih.gov/12472787/)
26. Drivsholm T, de Fine Olivarius N, Nielsen ABS, Siersma V. Symptoms, signs and complications in newly diagnosed type 2 diabetic patients, and their relationship to glycaemia, blood pressure and weight. *Diabetologia*. 2005; 48(2):210–4. PMID: [15650820](https://pubmed.ncbi.nlm.nih.gov/15650820/)
27. Edwards K, Pritchard N, Vagenas D, Russell A, Malik RA, Efron N. Utility of corneal confocal microscopy for assessing mild diabetic neuropathy: baseline findings of the LANDMark study. *Clinical and Experimental Optometry*. 2012; 95(3):348–54. doi: [10.1111/j.1444-0938.2012.00740.x](https://doi.org/10.1111/j.1444-0938.2012.00740.x) PMID: [22540156](https://pubmed.ncbi.nlm.nih.gov/22540156/)
28. Lorenzi M, Feke GT, Pittler L, Berisha F, Kolodjaschna J, McMeel JW. Defective myogenic response to posture change in retinal vessels of well-controlled type 1 diabetic patients with no retinopathy. *Investigative Ophthalmology & Visual Science*. 2010; 51(12):6770–5.
29. Rassam S, Patel V, Kohner E. The effect of experimental hypertension on retinal vascular autoregulation in humans: a mechanism for the progression of diabetic retinopathy. *Experimental Physiology*. 1995; 80(1):53–68. PMID: [7734138](https://pubmed.ncbi.nlm.nih.gov/7734138/)
30. Ra H, Yoo JH, Ban WH, Song HC, Lee SS, Kim SR, et al. Predictors for diabetic retinopathy in normoalbuminuric people with type 2 diabetes mellitus. *Diabetology & Metabolic Syndrome*. 2012; 4(1):29.
31. Bitirgen G, Ozkagnici A, Malik R, Kerimoglu H. Corneal nerve fibre damage precedes diabetic retinopathy in patients with Type 2 diabetes mellitus. *Diabetic Medicine*. 2014; 31(4):431–8. doi: [10.1111/dme.12324](https://doi.org/10.1111/dme.12324) PMID: [24117485](https://pubmed.ncbi.nlm.nih.gov/24117485/)